

Third-generation minimally invasive correction of hallux valgus: technique and early outcomes

Kit Brogan · Tom Voller · Chris Gee · Tamas Borbely · Simon Palmer

Received: 31 May 2014 / Accepted: 6 August 2014
© SICOT aisbl 2014

Abstract

Purpose There is growing evidence supporting minimally invasive surgical (MIS) techniques for correction of symptomatic hallux valgus. The aim of this study was to present a hybrid third-generation technique and assess the safety and efficacy from the first 45 procedures.

Methods Forty-five consecutive feet underwent a third-generation MIS distal chevron osteotomy with a minimum six month follow-up (range six to 17 months). This technique uses both first- and second-generation techniques plus a distal chevron osteotomy and screw for improved control and stabilisation of the metatarsal head. All patients were clinically assessed using the Manchester–Oxford Foot Questionnaire (MOXFQ). Radiographic measures included hallux valgus angle (HVA), intermetatarsal angle (IMA), first metatarsal length and overall toe length.

Results There were significant improvements in all three domains of the MOXFQ ($p < 0.001$). There was also significant improvement in all radiographic parameters ($p < 0.001$). Mean HVA decreased from 30.54° to 10.41° , and the mean IMA decreased from 14.55° to 7.11° . Shortening of the first

metatarsal had no effect on clinical outcomes. There was a very low rate of complications.

Conclusion The short-term results of this third-generation technique show that it is a safe procedure with good clinical outcomes and compares favourably with earlier techniques.

Keywords Hallux valgus · Bunion · Minimally invasive · MIS · Chevron

Introduction

Hallux valgus is a common condition with progressive abduction and pronation of the first phalanx, adduction, pronation and elevation of the first metatarsal (MT) and lateral capsular retraction of the first metatarsophalangeal joint (MTPJ). Pain and discomfort are felt because of inflammation of the bursa overlying the medial eminence, and irritation of the dorsal cutaneous nerve. There have been >150 procedures described for the treatment of hallux valgus, but as yet there is no consensus on the best method.

Distal MT chevron osteotomy is a good option in mild to moderate hallux valgus, providing good results in deformity correction and in symptom relief [1]. In the last decade, there has been a growing interest in the use of minimally invasive techniques for the treatment of this condition, but a recent review article concluded that there was not enough evidence to favour minimally invasive surgery (MIS) over traditional open techniques [2, 3]. This was largely owing to the fact that the majority of published series were case series without comparison or control groups. The technique described in this paper is a modification of the minimally invasive chevron and akin (MICA) technique described by Redfern and Vernois, [4], which uses some parts of the original Bosch and, later, SERI (simple, effective, rapid and inexpensive), techniques [5, 6]. Minimally invasive techniques are being adopted in all

K. Brogan (✉) · T. Voller · C. Gee · S. Palmer
Department of Orthopaedics, Western Sussex NHS trust, Worthing
Hospital, Worthing BN11 2DH, UK
e-mail: kitbrogan@mac.com

T. Voller
e-mail: tomvoller@hotmail.com

C. Gee
e-mail: chrisgeemrcs@gmail.com

S. Palmer
e-mail: Simon.Palmer@wsht.nhs.uk

T. Borbely
School of Psychology, University of Sussex, Brighton BN1 9QH,
UK
e-mail: t.borbely@sussex.ac.uk

surgical specialties essentially because of the advantages to soft tissues. This has the theoretical advantages of decreasing recovery and rehabilitation times, thereby reducing the morbidity associated with both the disease process and the operative intervention. In hallux valgus surgery in particular, minimally invasive techniques have the potential added benefits for patients in whom wound healing is a problem. The aim of this study was to describe this new, third-generation MIS technique and review early clinical and radiological outcomes.

Materials and methods

Institutional review board approval was obtained for this prospective cohort study. A total of 45 consecutive feet (35 patients) with symptomatic hallux valgus underwent a third-generation MIS correction by the senior author. Baseline characteristics are shown in Table 1. Patients were excluded from the study if they required additional foot procedures at the same time; this was done to reduce potential confounding factors.

Radiographic analysis was performed on standard weight-bearing anteroposterior and lateral radiographs. Hallux valgus angle (HVA) was categorised as mild ($15\text{--}20^\circ$), moderate ($21\text{--}39^\circ$) and severe ($\geq 40^\circ$). Intermetatarsal angle (IMA) was categorised as mild ($9\text{--}11^\circ$), moderate ($12\text{--}17^\circ$) and severe ($\geq 18^\circ$). Additional radiographic measures included toe length (base of first MT to tip of distal phalanx), first MT length and plantar offset (amount of plantar translation of MT head following osteotomy). Radiographic analysis was performed by a single observer (KB).

All patients were clinically assessed pre- and postoperatively with the Manchester–Oxford Foot Questionnaire (MOXFQ), which was designed as an outcome measure following hallux valgus surgery and is as effective as and comparable with AOFAS and the Short-Form Health Survey of 36 Questions (SF-36) [7]. There are three domains: Walking/Standing (seven items); Pain (five items); and Social Interaction (four items) scores. Response options consist of a five-point Likert scale ranging from no to maximal limitation. An individual score is used for each domain and converted into a metric score from 0–100, where 100=most severe. The MOXFQ was designed to be interpreted as three separate scores, although a recent study [8] suggested that summation of the three domains, similar to the AOFAS score, also has validity. All complications were recorded.

Third-generation MIS technique

Surgery is performed with patients supine with an ankle tourniquet. Antibiotics are given on anaesthesia induction. After a standard prep, 20 ml 0.5 % marcaine Mayo block

Table 1 Baseline patient characteristics

Patients undergoing MIS for symptomatic hallux valgus ($n=45$)	
Age mean (SD)	54 Years (10.9)
Gender: F/M	45/1
Unilateral/bilateral	25/10

SD standard deviation

is inserted. If neutral alignment of the great toe cannot be achieved with varus pressure on the toe, then percutaneous release of the fibular sesamoid ligaments and conjoined tendon of the adductor hallucis tendon is undertaken using an image intensifier. In an earlier study by the senior author, the incidence of release during MIS distal chevron was 10 % [9]. Neutral alignment of the toe with relocation of the sesamoids under the MT head is then checked using the image intensifier. A stab incision is made adjacent to the medial proximal nail fold, and a 1.8-mm titanium wire is inserted superficial to the periosteum of the distal phalanx of the toe, stopping short of the medial eminence of the first MT (Fig. 1). A 5-mm extensile incision is made over the first MT neck, cutaneous

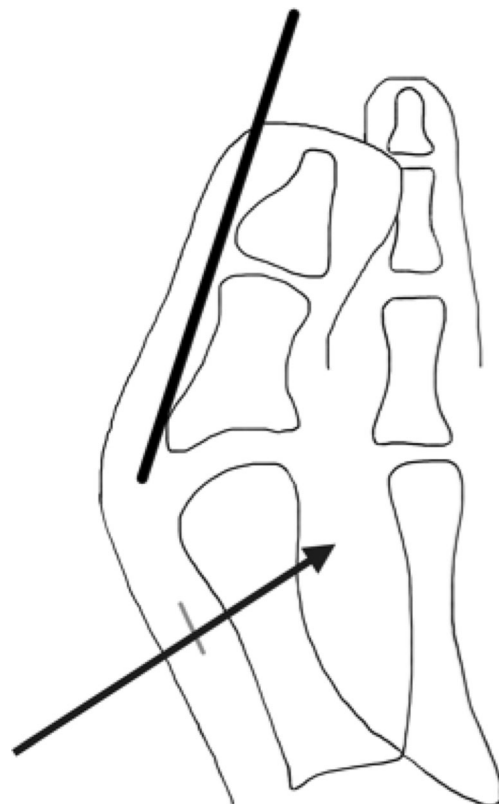


Fig. 1 First, a 1.8-mm titanium guidewire inserted extraperiosteally from nail fold to first metatarsal (MT) head. Second, a 5-mm incision is made over the MT neck, and the chevron osteotomy is made using the burr directed towards the head of the third MT

nerves are carefully sought and, if found, avoided and soft tissues are carefully spread down to bone. A mini periosteal elevator is passed around the first MT neck superiorly and inferiorly to create a deep soft-tissue pouch to provide a safe working area for the burr.

A 2 x 20-mm Shannon Burr (WG Healthcare, UK) on a console set at 50 NM torque and 250 rpm is used to create a perpendicular hole in the first MT neck. This is angled distally towards the third MT head and plantarward by 20° (Fig. 1). This is checked on the image intensifier. Superior and inferior side cuts are made to complete the chevron shape. The inferior limb is longer than the superior limb of the bony cut (Fig. 2). The 1.8-mm titanium wire is then advanced into the incision. Using a mosquito clip, the wire is gently introduced into the intramedullary canal of the first MT. This causes lateral, distal and plantar displacement of the first MT head (Fig. 3), thereby creating a 3D correction of the deformity, as seen in other described techniques [10] with good outcomes. The position is checked on the image intensifier, and the wire is advanced to the base of the first MT.

Once the position is accepted, a separate stab incision is made 2 cm proximal and medial to the osteotomy site. A 1.1-mm guidewire is inserted at this point obliquely and advanced across the osteotomy site into the MT head, remaining outside the joint surface (Fig. 4). This is measured, drilled and countersunk, and an appropriate Barouk-type screw is inserted over the wire (Fig. 4). Anteroposterior (AP) and lateral views are taken at the end of the procedure. The wound is closed with a 4.0 nylon mattress suture after irrigation, and the screw incision is closed with a steristrip. The 1.8-mm wire is bent and cut short distally, dressed with Jelonet and gentamicin sponge and the foot is dressed with gauze, wool and crepe.

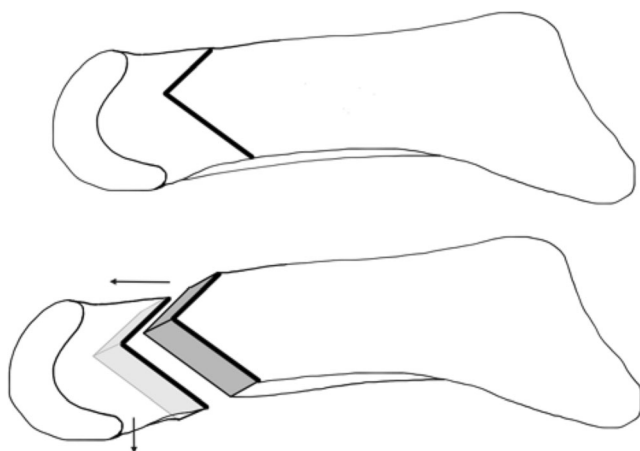


Fig. 2 Lateral view of chevron osteotomy with longer plantar than dorsal limb and distal and plantar angle, thereby allowing increased length and plantar offset

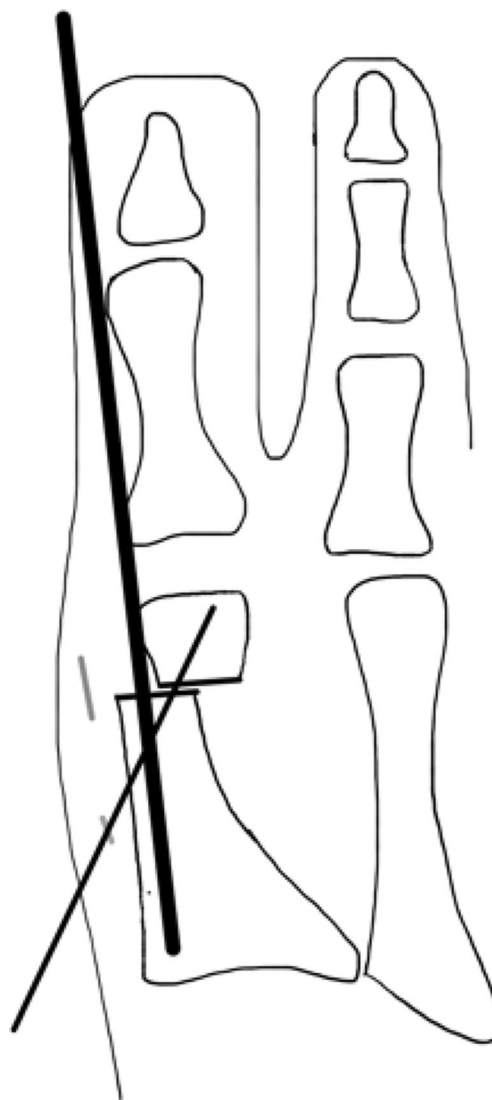


Fig. 3 The wire is inserted through the osteotomy site, causing lateral, distal and plantar displacement of the first metatarsal (MT) head. A guidewire is inserted across the osteotomy through a separate stab incision. This is measured, drilled and countersunk

Postoperative management

The patient is allowed to bear weight on the heel while wearing a surgical shoe, and the K-wire is removed four weeks postoperatively. A removable Valgulok (Bauerfind, Germany) splint is then applied, but the patient is encouraged to remove this ten to 15 times a day to mobilise the first MTPJ. The patient is allowed to increase their weight bearing over the entire foot at this point. A standing AP and lateral radiograph is taken at six to eight weeks to ensure bony healing.

Statistics

Data were analysed using the IBM SPSS 20 statistical package. In order to investigate the effect of MT length change on

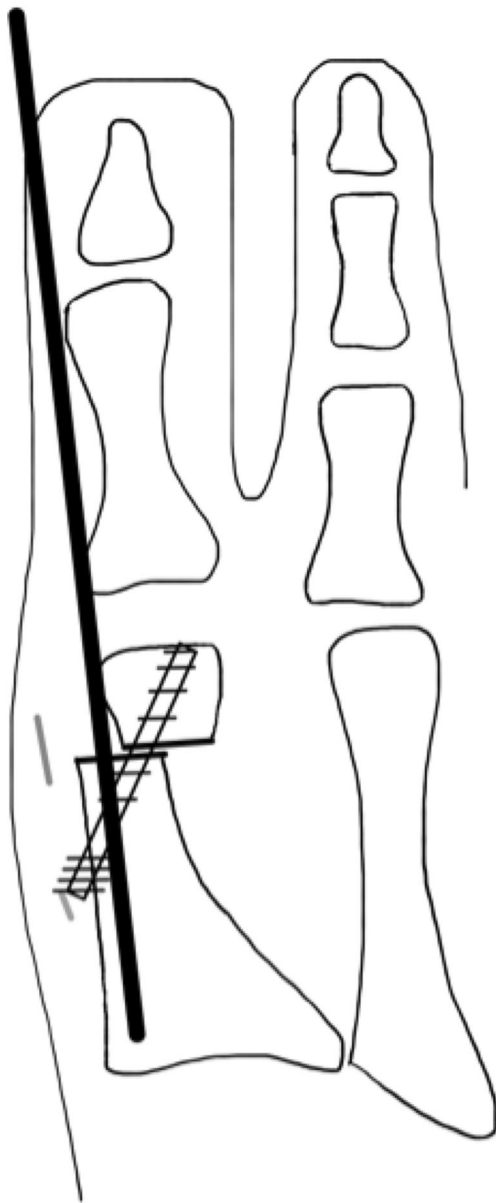


Fig. 4 Appropriate-length Barouk screw is inserted across the osteotomy, and the guide-wire is removed

clinical outcomes, one-way repeated-measures analyses of covariance (ANCOVA) were carried out on pre- and postoperative MOXFQ scores, with the change in pre- and postoperative MT length used as a covariate. Preliminary power calculations revealed that our study had a moderate to high power of 0.60 to detect a medium-sized effect (Cohen's $d=0.5$).

Results

Table 2 shows preoperative radiological severity. The majority of patients (74 %) was classed as moderate. Table 3 shows

Table 2 Preoperative radiological severity prior to minimally invasive surgery

Angle	Degree of severity	Patients $n=42$
Hallux valgus	Mild (15–20°)	5 (12 %)
	Moderate (21–39°)	31 (74 %)
	Severe ($\geq 40^\circ$)	6 (14 %)
Intermetatarsal	Mild (9–11°)	5 (12 %)
	Moderate (12–17°)	31 (74 %)
	Severe ($\geq 18^\circ$)	6 (14 %)

radiological and clinical results. Mean follow-up period was 9.1 (range six to 17) months. No patients were lost to follow-up.

Clinical

One patient only completed their preoperative pain score; thus, postoperative pain score, and not social interaction or walking scores, was used. There was a statistically significant ($p<.001$) improvement in all three domains of the MOXFQ: Walking score improved from 43.17 to 9.84; Pain score improved from 50.80 to 17.44; Social Interaction score improved from 47.59 to 13.06. In terms of combined MOXFQ score, there was an average improvement from 141.56 to 40.34 ($p<.001$). MT length change did not have a significant effect on improvement in Walking ($p = 0.844$), Pain ($p = 0.502$) or Social Interaction ($p = 0.717$) scores. Pearson's product-moment correlations revealed no significant links between MT length change and improvement on any of the clinical outcome variables.

Radiological

Three feet were excluded from radiological analysis due to incomplete sets of radiographs, leaving 42 feet for review. Mean HVA decreased from 30.54° to 10.41° ($p<0.001$) and mean IMA from 14.55° to 7.11° ($p<0.001$). Mean MT length decreased by 5 mm (range -3 to 15 mm; SD 4.4), but mean overall toe length decreased by only 2 mm (range -11 to 13 mm; SD 6.6) ($p .093$). The average plantar offset achieved was 2.67 mm (range 0–4.6 mm). Table 4 shows radiological comparison of this technique with other published MIS series, indicating a greater degree of correction compared with other studies.

Complications

One patient experienced screw back-out, which required removal but with no loss of position on serial radiographs. One patient complained of prominent metalwork although elected to leave the screw in situ; one patient complained of increased

Table 3 Radiological and clinical results following minimally invasive surgery

Variables	Mean		SD	P value
	Mean	SD		
Follow-up duration (Months)	9.1	3		
Radiological assessment				
IMA (°)	Preoperative	14.55	2.5	
	Postoperative	7.11	2.7	
	Difference	7.44		<0.001
HVA (°)	Preoperative	30.54	8	
	Postoperative	10.41	5.04	
	Difference	20.13	2.96	<0.001
Toe length (mm)	Preoperative	116.05	11.8	
	Postoperative	114.52	12.6	
	Difference	1.53		<0.001
MT length (mm)	Preoperative	60.49	4.4	
	Postoperative	55.5	4.98	
	Difference	4.99		<0.001
Plantar offset	Postoperative	2.67	1.65	N/A
Functional assessment scores				
Walking	Preoperative	43.17	20.49	
	Postoperative	9.84	17.29	
	Difference	33.33		<0.001
Pain	Preoperative	50.8	18.97	
	Postoperative	17.4	23.03	
	Difference	33.4		<0.001
Social interaction	Preoperative	47.59	19.41	
	Postoperative	13.06	21.03	
	Difference	34.53		<0.001

IMA intermetatarsal angle, HVA hallux valgus angle, MT metatarsal, SD standard deviation

foot cramping on swimming and limited walking distance, although no clinical or radiological reason was discovered. There was no avascular necrosis (AVN), infection, hallux varus, nonunion, dorsal malunion of the distal fragment, metatarsalgia and or incidence of recurrence.

Discussion

Results of this study support the use of this third-generation technique. First-generation minimally invasive techniques were originally described by Bosch [5]; a second-generation modification using a screw for fixation was subsequently described [4]. The original Bosch technique of using an axial wire is a very powerful way of displacing the MT head and is further enhanced with the application of a screw and a chevron-shaped bone cut to improve stability. This technique also addresses other aspects of the deformity that are difficult to correct and control with other techniques, such as plantar displacement and lengthening of the distal fragment. This is an extracapsular procedure and therefore protects the blood supply to the MT head [5]. Being extra-articular, it is also protective of postoperative stiffness associated with open techniques, which are reported as being as high as 38 % [11]. In addition, because a low-speed, high-torque burr is used, a smaller incision is possible compared with most other MIS series [5, 12–16].

One criticism of using a burr is that it can shorten the first MT, thus causing transfer metatarsalgia [17], although there is no consensus on the amount of shortening that might lead to pain. In Turnbull and Grange's [18] series, they found shortening of up to 8 mm acceptable, and our study found no correlation between degree of shortening and clinical outcome. Overcorrection into hallux varus has not been reported with MIS, and this may be due to the absence of medial soft-tissue tightening. The amount of translation can be as much as 90 %, and this relaxes the adductor hallucis tendon. It remains to be seen whether or not the lack of soft-tissue repair causes the deformity to recur, although Giannini et al. [6] did not find this to be the case in their study, which had a >five year follow-up; Faour-Martin et al. [19] also found results of their MIS technique were sustained over a ten year period.

Kadokia et al. [20] reported an unacceptable complication rate associated with MIS bunion surgery, which included osteonecrosis, malunion, nonunion, dorsal

Table 4 Comparison of radiographic correction between studies

Study	Pre-op mean IMA (°)	Post-op mean IMA (°)	Difference (°)	Pre-op mean HVA (°)	Post-op mean HVA (°)	Difference (°)
Maffuli et al. [16]	11.5	7.5	4	32	14.1	17.9
Magnan et al. [23]	12.3	7.3	5	31.5	13.7	16.8
Bauer et al. [24]	13	10	3	28	14	14
Radwan et al. [13]	12.55	7.79	4.76	27.59	13.14	14.45
Huang et al. [14]	11.9	7.2	4.7	26.7	15.5	11.2
Sun et al. [12]	11.8	6.8	5	33.3	12.3	21
This study	14.55	7.11	7.44	30.54	10.41	20.13

Pre-op preoperative, Post-op postoperative, IMA intermetatarsal angle, HVA hallus vagus angle

displacement and recurrence. It has been suggested this may be due to the older age of their patient cohort (mean 52 vs 54 years in our study). Another possible reason for their poor outcomes could be their early weight-bearing strategy, whereas we limit weight bearing in a rigid-soled shoe until four weeks. There is the only study reported with such a high complication rate and may represent the steep learning curve associated with MIS.

Peng-Ju et al. [14], using a first-generation technique, recommended that only mild–moderate hallux valgus should be treated minimally invasively, and whereas the use of MIS in severe hallux valgus has been previously reported [21], an upper limit of IMA of 19° is recommended by the senior author when using our technique.

The follow-up period is relatively short in our study, and a longer-term study is required. The lack of a control or comparison group is significant, and this should also be undertaken as future research. Other studies have looked at sesamoid position, [13, 12], but our hospital changed its computer-based X-ray system and we were unable to reaccess images to perform this analysis. Wilson et al., however, found no significant correlation between sesamoid position and outcome [22]. There is no doubt that MIS hallux valgus surgery has a steep learning curve, and our results may therefore be difficult to reproduce.

Conclusion

We conclude that the third-generation MIS technique is a safe and effective procedure for correcting symptomatic moderate hallux valgus, but longer-term studies with comparison groups are important.

Conflict of interest None.

References

- Schneider W, Aigner N, Pinggera O, Knahr K (2004) Chevron osteotomy in hallux valgus. Ten-year results of 112 cases. *J Bone Joint Surg Br* Vol 86(7):1016–1020
- Maffulli N, Longo UG, Marinozzi A, Denaro V (2011) Hallux valgus: effectiveness and safety of minimally invasive surgery. A systematic review. *Br Med Bull* 97:149–167. doi:10.1093/bmb/ldq027
- Trnka HJ, Krenn S, Schuh R (2013) Minimally invasive hallux valgus surgery: a critical review of the evidence. *Int Orthop* 37(9):1731–1735. doi:10.1007/s00264-013-2077-0
- Walker RD (2012) Minimally Invasive Hallux Valgus Correction: The MICA technique. *J Bone Joint Surg Br* Vol 94-B(Suppl XXII):38
- Bosch P, Wanke S, Legenstein R (2000) Hallux valgus correction by the method of Bosch: a new technique with a seven-to-ten-year follow-up. *Foot Ankle Clin* 5(3):485–498, v-vi
- Giannini S, Faldini C, Nanni M, Di Martino A, Luciani D, Vannini F (2013) A minimally invasive technique for surgical treatment of hallux valgus: simple, effective, rapid, inexpensive (SERI). *Int Orthop* 37(9):1805–1813. doi:10.1007/s00264-013-1980-8
- Dawson J, Boller I, Doll H, Lavis G, Sharp R, Cooke P, Jenkinson C (2012) Responsiveness of the Manchester-Oxford Foot Questionnaire (MOXFQ) compared with AOFAS, SF-36 and EQ-5D assessments following foot or ankle surgery. *J Bone Joint Surg Br* Vol 94(2):215–221. doi:10.1302/0301-620X.94B2.27634
- Morley D, Jenkinson C, Doll H, Lavis G, Sharp R, Cooke P, Dawson J (2013) The Manchester-Oxford Foot Questionnaire (MOXFQ): Development and validation of a summary index score. *Bone Joint Res* 2(4):66–69. doi:10.1302/2046-3758.24.2000147
- Morgan SR, Benerjee I, Palmer RS (2012) Minimally Invasive chevron osteotomy; functional outcome and comparison with open chevron osteotomy. *J Bone Joint Surg Br* Vol 94-B(Suppl XLIII):67
- Lucijanic I, Bicanic G, Sonicki Z, Mirkovic M, Pecina M (2009) Treatment of hallux valgus with three-dimensional modification of Mitchell's osteotomy: technique and results. *J Am Podiatr Med Assoc* 99(2):162–172
- Austin DW, Leventen EO (1981) A new osteotomy for hallux valgus: a horizontally directed "V" displacement osteotomy of the metatarsal head for hallux valgus and primus varus. *Clin Orthop Relat Res* 157:25–30
- Sun WD, Wen JM, Hu HW, Sun YS, Sang ZC, Jiang KW, Liang Z, Cheng T, Lin XX, Wu XB, Dai HL (2010) Long term efficacy of minimal incision osteotomy for hallux abducto valgus. *Orthop Surg* 2(3):223–228. doi:10.1111/j.1757-7861.2010.00091.x
- Radwan YA, Mansour AM (2012) Percutaneous distal metatarsal osteotomy versus distal chevron osteotomy for correction of mild-to-moderate hallux valgus deformity. *Arch Orthop Trauma Surg* 132(11):1539–1546. doi:10.1007/s00402-012-1585-5
- Huang PJ, Lin YC, Fu YC, Yang YH, Cheng YM (2011) Radiographic evaluation of minimally invasive distal metatarsal osteotomy for hallux valgus. *Foot Ankle Int / Am Orthop Foot Ankle Soc Swiss Foot Ankle Soc* 32(5):S503–507. doi:10.3113/FAI.2011.0503
- Lin YC, Cheng YM, Chang JK, Chen CH, Huang PJ (2009) Minimally invasive distal metatarsal osteotomy for mild-to-moderate hallux valgus deformity. *Kaohsiung J Med Sci* 25(8):431–437. doi:10.1016/S1607-551X(09)70538-8
- Maffulli N, Oliva F, Coppola C, Miller D (2005) Minimally invasive hallux valgus correction: a technical note and a feasibility study. *J Surg Orthop Adv* 14(4):193–198
- Jung HG, Zaret DI, Parks BG, Schon LC (2005) Effect of first metatarsal shortening and dorsiflexion osteotomies on forefoot plantar pressure in a cadaver model. *Foot Ankle Int / Am Orthop Foot Ankle Soc Swiss Foot Ankle Soc* 26(9):748–753
- Turnbull T, Grange W (1986) A comparison of Keller's arthroplasty and distal metatarsal osteotomy in the treatment of adult hallux valgus. *J Bone Joint Surg Br* Vol 68(1):132–137
- Faour-Martin O, Martin-Ferrero MA, Valverde Garcia JA, Vega-Castrillo A, de la Red-Gallego MA (2013) Long-term results of the retrocapital metatarsal percutaneous osteotomy for hallux valgus. *Int Orthop* 37(9):1799–1803. doi:10.1007/s00264-013-1934-1
- Kadokia AR, Smerek JP, Myerson MS (2007) Radiographic results after percutaneous distal metatarsal osteotomy for correction of hallux valgus deformity. *Foot Ankle Int / Am Orthop Foot Ankle Soc Swiss Foot Ankle Soc* 28(3):355–360. doi:10.3113/FAI.2007.0355
- De Lavigne C, Rasmont Q, Hoang B (2011) Percutaneous double metatarsal osteotomy for correction of severe hallux valgus deformity. *Acta Orthop Belg* 77(4):516–521
- Wilson JD, Baines J, Siddique MS, Fleck R (2009) The effect of sesamoid position on outcome following scarf osteotomy for hallux abducto valgus. *Foot Ankle Surg: Off J Eur Soc Foot Ankle Surg* 15(2):65–68. doi:10.1016/j.fas.2008.07.002

23. Magnan B, Pezze L, Rossi N, Bartolozzi P (2005) Percutaneous distal metatarsal osteotomy for correction of hallux valgus. *J Bone Joint Surg Am* Vol 87(6):1191–1199. doi:[10.2106/JBJS.D.02280](https://doi.org/10.2106/JBJS.D.02280)
24. Bauer T, de Lavigne C, Biau D, De Prado M, Isham S, Laffenetre O (2009) Percutaneous hallux valgus surgery: a prospective multicenter study of 189 cases. *Orthop Clin N Am* 40(4):505–514. doi:[10.1016/j.ocl.2009.05.002](https://doi.org/10.1016/j.ocl.2009.05.002), ix